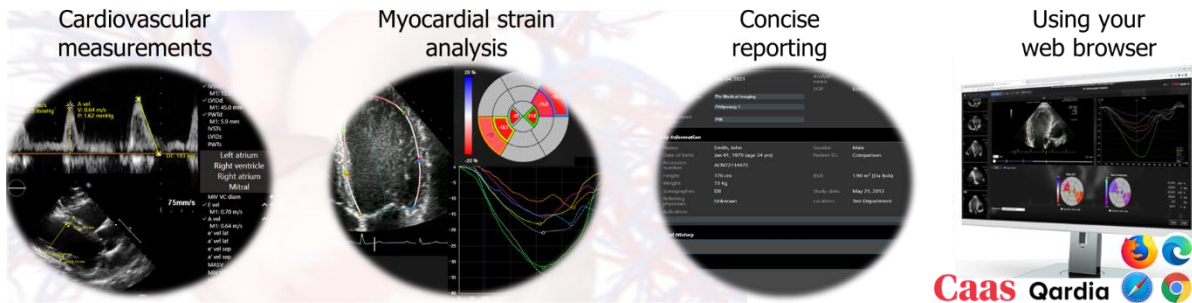


Whitepaper: A.I. driven myocardial strain analysis

The Caas Qardia echocardiography analysis platform



The Caas Qardia platform offers a comprehensive toolbox for review, analysis, and reporting of your patient’s echocardiographic exams. Perform chamber quantification, valve analysis (including PISA measurements), diastolic function assessment and more. Vendor-neutral, runs in a web environment, and works with any PACS. Furthermore, Caas Qardia features a validated and state-of-the-art myocardial strain analysis workflow.

What is myocardial strain analysis?

Myocardial strain analysis uses echocardiographic images of the heart to quantify the cyclic deformation of the myocardium.

Estimation of myocardial strain can be achieved using *speckle-tracking* applied to B-mode images. Speckles may be recognized as tiny bright spots on echo images surrounding the heart and other organs. Of special interest are speckles located around the *left ventricular endocardium* (Fig. 1). By using a speckle-tracking algorithm, the Caas Qardia software identifies for each image frame within the heartbeat the speckle positions. These estimated speckle positions provide a means of mapping myocardial deformation.

Clinically, the deformation parameter of interest is the longitudinal strain^{1,2}. Under normal ventricular contraction, longitudinal strain becomes negative from the onset of contraction of the ventricle. The more negative strain becomes the greater is the contraction. The longitudinal strain magnitude may be used as a proxy for the patient’s cardiac function. In some cardiac diseases, regions of the myocardium may exhibit abnormal strain behaviour, e.g. diseased regions during ventricular contraction may become instead stretched, which results in positive strain signals for these regions.

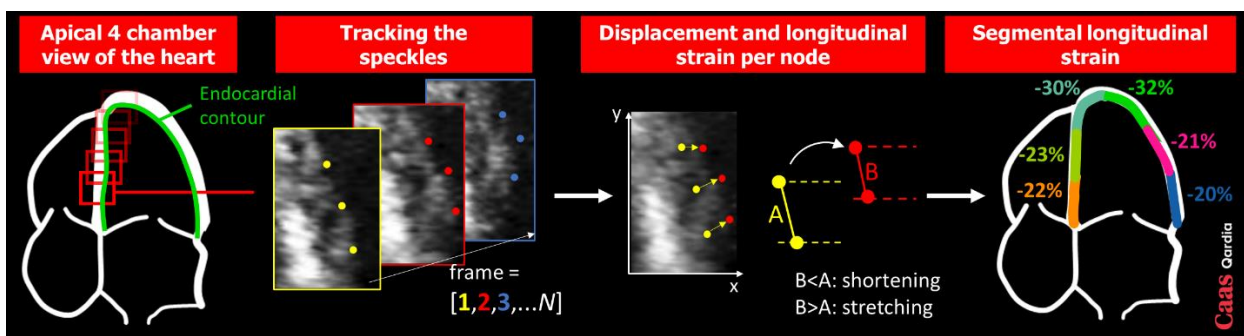


Figure 1: Flowchart explaining the speckle tracking approach to assess longitudinal strain in patients.

Segmental longitudinal strain can be calculated as outlined in Fig 1. *Global longitudinal strain* (GLS) is derived from the total endocardial line length of the tracked contour (Fig. 1). Its formula reads $GLS = (L_s - L_{ref}) / L_{ref} \cdot 100\%$, where L_{ref} represents the contour's reference length, usually defined at the time of end-diastole, and L_s is the length at the time of end-systole, peak-systole or at peak strain³.

Myocardial strain analysis supports you in diagnostics and clinical decision-making

The European (EACVI) and American (ASE) echocardiography societies recommend reporting left ventricular myocardial strain analysis alongside ejection fraction in the workup of echo exams¹. Compared to ejection fraction, the GLS is considered a more sensitive parameter for systolic function and is found to be of added value in a wide range of patient groups.

Table 1: Examples of the potential clinical utility of myocardial strain analysis.

Potential of myocardial strain analysis for clinical scenarios	
Patients receiving cancer therapeutics	A 15% relative reduction in GLS from baseline in serial follow-up of patients is used to detect cardiac damage inflicted by the chemotherapy (so-called cancer therapeutics related cardiac dysfunction, CTRCD) ⁴ .
Ischaemic heart disease (IHD) patients	In patients with acute coronary occlusion, GLS may serve as strong marker for infarct size, as previously validated in IHD patients using cardiac MR ⁵ .
Hypertrophic cardiomyopathy (HCM) patients	Regional strain information informs about the location of hypertrophy. Furthermore, meta-analysis of over 3,000 subjects showed that abnormal GLS is a strong predictor of adverse outcomes in HCM patients ⁶ .

Caas Qardia renders myocardial strain analysis straightforward

Caas Qardia's *A.I.-driven* workflow does not only drastically reduce your analysis time, but also improves the reproducibility of the analysis. The only required user action is selecting the correct echo view. Caas Qardia automatically performs contour segmentation and speckle-tracking. The resulting segmental tracking, strain curves and global strain values are automatically populated in a concise exam report and DICOM Structured Report (Fig. 2). A session state can be saved locally or pushed to your PACS to save and restore previous analyses.

Key results

- Global longitudinal strain (GLS) for left- and right ventricles
- Segmental peak/end-systolic/peak-systolic- and time-to-peak strains
- Global and segmental strain-time curves
- Major axis lengths
- Additional deformation and motion parameters
 - Wall motion, strain rate, and wall velocity

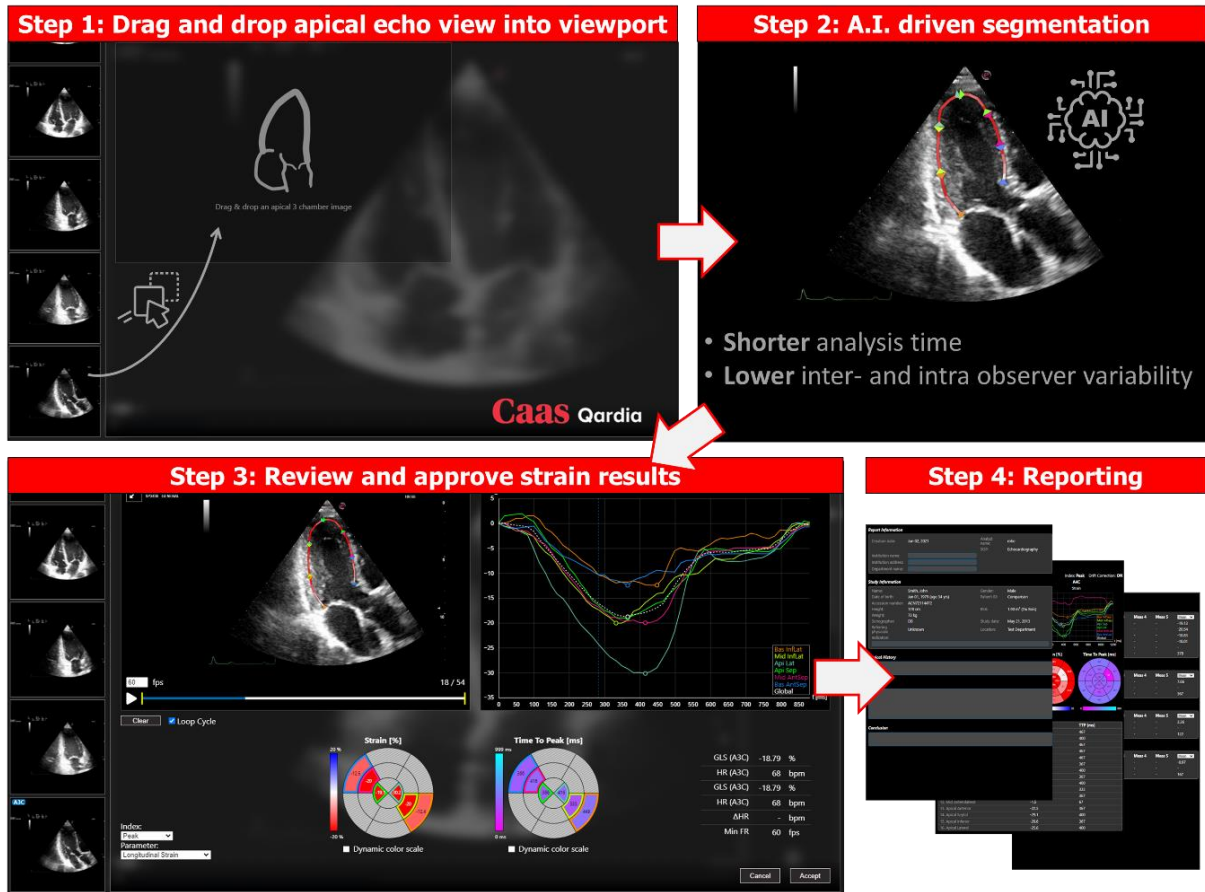


Figure 2: The Caas Qardia strain analysis workflow.

Quality control in myocardial strain analysis

Correct acquisition of apical echo views is vital to obtain credible strain results. A common problem lies in foreshortening of images during acquisition⁷ (Fig. 3). Foreshortening results in an abnormally thick false apex and an apparently shortened left ventricle⁷. Analyzing foreshortened apical images may falsely suggest an increase in strain magnitude, when comparing results to an optimal view from the same patient (Fig. 4).

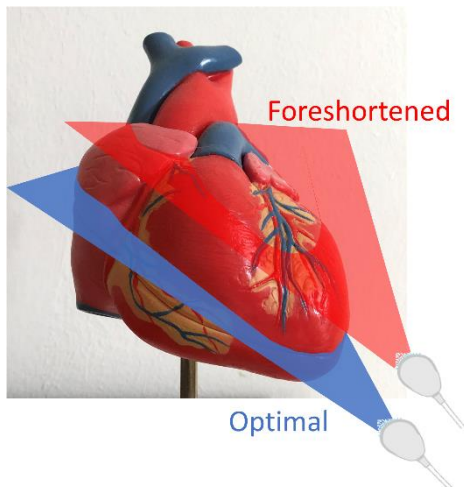
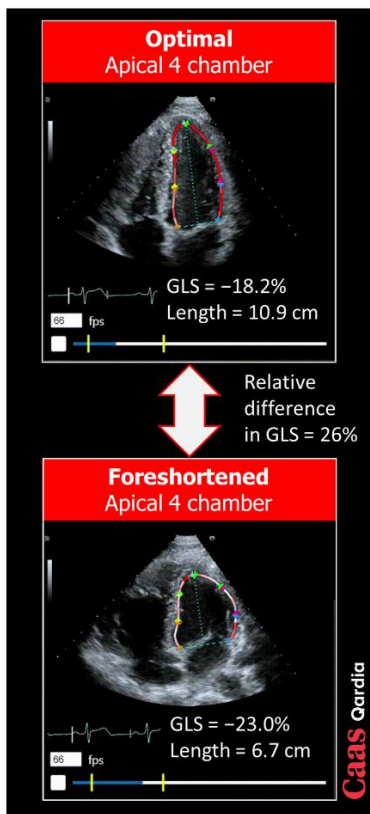


Figure 3: Illustration of foreshortening in 2D echocardiographic imaging of the left ventricle. The imaging plane indicated in blue cuts through the true apex, while the red imaging plane does not.



Caas Qardia reports to the user, as quality control information, the major axis length of the ventricle which is deemed useful for detection of foreshortening⁷. Comparing strain results between individual views obtained in a patient or between patient visits, as rule-of-thumbs, a relative difference in major axis length of no more than 10% should exist.

Figure 4: Example on the impact of foreshortening on GLS based on apical 4 chamber views acquired in the same patient on the same day. Top: Optimal apical 4 chamber with GLS of -18.2% with major axis length of 10.9 cm, bottom: Foreshortened apical 4 chamber with GLS of -23.0% with major axis length of 6.7 cm.

Clinical validation

The Caas Qardia myocardial strain workflow has been independently validated at Cardialysis Core Laboratories against the TomTec 2D CPA strain package (TomTec Imaging Systems GmbH). This comparative evaluation was performed by Dr. Ernest Spitzer and Dr. Claire Ren.

Reference to full text publication (open access):

Spitzer E, Camacho B, Mrevlje B, Brandenburg HJ, Ren CB. Echocardiography Core Laboratory Validation of a Novel Vendor-Independent Web-Based Software for the Assessment of Left Ventricular Global Longitudinal Strain. *J Cardiovasc Imaging* 2023;31:e20. <https://doi.org/10.4250/jcvi.2022.0130>

Conclusions

- Myocardial strain analysis has established its place alongside ejection fraction assessment in the standard transthoracic echocardiography exam workup.
- Caas Qardia allows for fast, reproducible, and reliable myocardial strain analysis, regardless of what vendor echo machine was used to obtain the data.

Interested in test-driving Caas Qardia using your own data?

Please contact: pmi-sales@pie.nl or visit our website: www.piemedicalimaging.com

References

1. King A, Thambyrajah J, Leng E, Stewart MJ. Global longitudinal strain: a useful everyday measurement? *Echo Res Pract.* 2016;3(3):85-93. doi:10.1530/ERP-16-0022
2. Lang RM, Badano LP, Victor MA, et al. Recommendations for cardiac chamber quantification by echocardiography in adults: An update from the American Society of Echocardiography and the European Association of Cardiovascular Imaging. *J Am Soc Echocardiogr.* Published online 2015. doi:10.1016/j.echo.2014.10.003
3. Voigt J, Pedrizzetti G, ... PL-EH, 2015 undefined. Definitions for a common standard for 2D speckle tracking echocardiography: consensus document of the EACVI/ASE/Industry Task Force to standardize deformation. *academic.oup.com.* Accessed August 13, 2020. <https://academic.oup.com/ehjcmaging/article-abstract/16/1/1/2403449>
4. Plana JC, Galderisi M, Barac A, et al. Expert consensus for multimodality imaging evaluation of adult patients during and after cancer therapy: A report from the American Society of Echocardiography and the European Association of Cardiovascular Imaging. *Eur Heart J Cardiovasc Imaging.* Published online 2014. doi:10.1093/ehjci/jeu192
5. Joseph G, Zaremba T, Johansen MB, et al. Echocardiographic global longitudinal strain is associated with infarct size assessed by cardiac magnetic resonance in acute myocardial infarction. *Echo Res Pract.* 2019;6(4):81-89. doi:10.1530/ERP-19-0026
6. A T-R, D M, A T, HM L, ZB P, MY D. Prognostic Value of Global Longitudinal Strain in Hypertrophic Cardiomyopathy: A Systematic Review of Existing Literature. *JACC Cardiovasc Imaging.* 2019;12(10):1930-1942. doi:10.1016/J.JCMG.2018.07.016
7. Ünlü S, Duchenne J, Mirea O, et al. Impact of apical foreshortening on deformation measurements: a report from the EACVI-ASE Strain Standardization Task Force. *Eur Hear J - Cardiovasc Imaging.* 2020;21(3):337-343. doi:10.1093/EHJCI/JEZ189

This document is provided on an "as is" basis and does not imply any guarantee or warranty, including the warranties of merchantability or fitness for a particular use. No product claims are based upon this document. The product claims applicable the Pie Medical Imaging products can be found in the user manuals accompanying the product.